

Role of diatoms in forensic diagnosis of drowning cases from Jammu & Kashmir, India

Ashiq Hussain Magrey and ¹Mool Raj*

Scientific Officer Forensic Science Laboratory, Jammu (J&K) India

¹PG Department of Biotechnology, Saifia Science College Bhopal, India

ABSTRACT

Diatom analysis is a valuable tool in forensic science and it is useful in diagnosis of drowning cases. The diatom test in drowning is based on the correlation between diatoms present in the medium where the possible drowning took place and inhalation of the sample water, which causes penetration of diatoms into the alveolar system and blood stream. These diatoms get deposited into the brain, kidneys sternum, femur bone and other organs. For solving of drowning cases, hard bones (sternum and clavicle) as well as soft tissues (lungs and liver) of drowned bodies and samples of water in which possible drowning take place are usually sent to the Forensic Science Laboratories for detection of diatoms. In the present study, 31 drowning human cases have been examined. Acid digestion test has been found to be one of the best methods for analyzing cases of forensic drowning. Results revealed from examination of 31 human drowning cases, 09 cases were positive (death due to drowning) while 22 cases were found to be negative.

KEY WORDS: FORENSIC DROWING CASES, DIATOMS, DETECTION

INTRODUCTION

Forensic science is the application of scientific methodology, knowledge and principles to the resolution of legal questions, whether criminal or civil. Death by drowning is defined as a death due to submersion in a

liquid and the mechanism in acute drowning is hypoxemia and irreversible cerebral anoxia¹. Although there are some typical signs of drowning known, it is still hard to determine a death by drowning when the post-mortem signs are impossible to find in case of deceased bodies. The diagnosis of drowning is one of the most

ARTICLE INFORMATION:

**Corresponding Author*

Received 28th April, 2014

Accepted after revision 21th June, 2014

BBRC Print ISSN: 0974-6455

Online ISSN: 2321-4007

© A Society of Science and Nature Publication, 2014. All rights reserved.

Online Contents Available at: <http://www.bbrc.in>

difficult diagnoses in forensic pathology and therefore a great number of tests have been proposed to allow a confirmation of death by drowning of a victim. Diatom test is one of these tests and works as an important tool in diagnosis of death due to drowning, it can be used to discriminate between drowning and non-drowning cases. Detection of diatoms in tissues may contribute to diagnosis of drowning, therefore an efficient method of extraction and microscopic examination of diatoms from tissues is fundamental. However, it is important to remember that the absence of diatoms does not immediately rule out drowning; the test does not prove the negative, and a thorough investigation is always required. (Peabody, 1978; Hürliemann *et al.*, 2000; James and Nordby, 2003; Thornton and Peterson, 2007; Houck and Seigal, 2010; Saferstein, 2010; Chisum and Turvey, 2011; Verma, 2013).

MATERIAL AND METHODS

The case studies were conducted in Biology Division of Forensic Science Laboratory Jammu (Jammu and Kashmir), India and all the cases reported here, are fresh water drowning cases. After post-mortem of dead bodies, internal organs (sternum, clavicle, femur and lungs) along with the water samples (from where the dead bodies were recovered) were sent as crime exhibits to the laboratory. Cases were opened and processed following standard methodology, (Peabody, 1978).

In all cases exhibits were put into different jars. 50 ml of nitric acid was added in each jar containing the sternum, clavicle, femur and lungs. Samples were left undisturbed overnight and boiled for half an hour on next day. A clear yellow solution was obtained with a fat layer at the top. The fat layer was discarded and the remaining samples were centrifuged at 4000 rpm for 10 minutes. The process of centrifugation was repeated three times in the same way. Supernatant was discarded and the pellets were washed with distilled water and re-centrifuged. Microscopic slides were prepared from the pellets after washing, dried on hot plate and studied under the microscope after applying immersion oil. Slides were also prepared from the water sample sent to the laboratory in which possible drowning took place. Comparison of diatom species found in organ sample and water sample was done and correlations were drawn out accordingly, (Hürliemann *et al.*, 2000)

EXTRACTION OF DIATOMS FROM WATER SAMPLES USING ACID DIGESTION METHOD

About 50 ml of water sample was transferred into a sterilized 100 ml glass beaker and 10-20 ml of concen-

trated nitric acid (HNO₃) was added to The bottles were shaken thoroughly before analyzing. The samples were analyzed with the help of 'Acid Digestion Method'. These samples were kept as such for two hours. Then the sample was centrifuged at 5000 rpm for 10 minutes in properly labeled plastic centrifuge tubes. The supernatant was pipette off leaving behind only a pellet containing diatom frustules at the bottom of tube. Pellet material was suspended in distilled water and centrifuged twice to remove all traces of acid (Peabody, 1978 and Hürliemann *et al.*, 2000)

PREPARATION OF SLIDES

After the final centrifugation except for 1ml, the whole supernatant was discarded by using a sterilized dropper. The pellet along with 1ml of supernatant was stirred well and entire volume of the pellet suspension (1 ml) was aspirated using a Pasteur pipette and droplets of the aspirate were poured. microscopic slides for each sample. Permanent slides were prepared in order to avoid the skipping of any diatom species. This material was completely dried and mounted with help of DPX. Diatoms were examined with an optical compound microscope fitted with light source at magnification of 1500X oil immersion. Slides were fully scanned with help of microscope and representative images of the diatom were captured using a computerized photo-capturing device/camera (Q-Win Leica) fitted on microscope objective lens.

RESULTS AND DISCUSSION

Out of 31 reported cases in the data, only selected few are being reported in the section of results, (Cases 1-11).

CASE 1

The body of a 19 year old boy was recovered from Dal lake three kms from Lalchowk, Srinagar. No signs of injury were found during the autopsy. Nitric acid extract of internal organs (sternum, clavicle, femur and lungs) revealed the presence of three types of diatom species (*Navicula lanceolata*, *Navicula oblonga* and *Gomphonema gracile*). The same three types of diatom species were found in the water sample from which the body was recovered. So the cause of death was assigned due to drowning.

CASE 2

The body of a 26 year old lady was recovered near the bank of Wular lake, the largest lake in Asia. Signs of head and neck injury were traced during autopsy. Nitric acid

extract of sternum and clavicle showed the absence of any diatom species. However, two diatom species (*Nitzschia subtilis* and *Navicula radiosa*) were detected in the water sample from where the body was found. The cause of death was attributed to the reasons other than drowning which was later accepted by her husband that he murdered her wife because of having extra-marital affair, thus it was proved that it was not a case of drowning.

CASE 3

The body of a 23 year old lady was recovered from a village well. No signs of injury were found during autopsy. Father of the lady claimed that her daughter was being murdered and then thrown into the well to prove the case as suicide. Nitric acid extracts of sternum, clavicle and femur showed presence of three diatom species (*Nitzschia gracilis*, *Cymbella* and *Navicula radiosa*). Same three types of diatom species were detected from the water sample of the well in which the body was found. Drowning was the cause of death.

CASE 4

The body of a 48 year old lady was recovered from a river Jehlum. No specific reason of death was found at autopsy. Microscopic studies of slides prepared from nitric acid extracts of sternum, clavicle, femur proved the presence of three diatom species (*Cymbella cymbiformis*, *Gomphonema spheroporum* and *Nitzschia frustulum*) which were the same species as traced from the water samples of river from which the body was recovered. Death was attributed to drowning. The family members also accepted that the lady was mentally disturbed and left the home a couple of days before the death.

CASE 5

A highly putrefied body of a 30 year old male was recovered from a Mansbal lake. No information about causes of death could be obtained at autopsy. Studies from extracts of nitric acid of sternum, clavicle and femur proved the presence of two species of diatom (*Cymbella ventricosa* and *Cocconeis placentula*). Water samples from multiple sites were sent to the laboratory to trace the original site of drowning. Same two types of diatom species were found in the water sample from a site distant from the site from where the body was recovered. The cause of death was drowning which was also proved by further police investigation.

CASE 6

The body of a 28 year old lady was recovered from a river Tawi in Jammu. No specific reason of death was

found at autopsy. Microscopic studies of slides prepared from nitric acid extracts of sternum, clavicle, femur proves the presence of three diatom species : *Amphora*; *Apipleura* and *Aulacoseria*, which were the same species as traced from the water samples of river from which the body was recovered. Death was attributed to drowning.

CASE 7

The body of a 16 year old boy was found submerged in a water tank. No sign of injury were found at autopsy. Nitric acid extract of internal organ (sternum) revealed the presence of two types of diatom species *Melosira* and *Hantzschna*. The same two types of diatom species were found in the water sample from which the body was recovered. So the cause of death was assigned due to drowning.

CASE 8

The body of a 34 year old lady was recovered from a canal. Signs of head and neck injury were traced during autopsy. Nitric acid extract of sternum and clavicle showed the absence of any diatom species. However, a diatom species (*Surirella*) were detected in the water sample from where the body was found. The cause of death was attributed to the reasons other than drowning which was later accepted by her mother in law that she murdered her.

CASE 9

The body of a 35 year old lady was recovered from a village well. No signs of injury were found during autopsy. Father of the lady claimed that her daughter was being murdered and then thrown into the well to prove the case as suicide. Nitric acid extracts of sternum, clavicle and femur showed the presence of two diatom species, *Eunotia* and *Epithemia*. Same two types of diatoms were detected from the water sample of well in which the body was found. Drowning was the cause of death.

CASE 10

The body of a 45 year old lady was recovered from a river Tawi in Jammu. No specific reason of death was found at autopsy. Microscopic studies of slides prepared from nitric acid extracts of sternum, proved the presence of diatom species *Anphora*, which was the same species as traced from the water sample of river (from which the body was recovered). Death was attributed to drowning. The family members also accepted that the lady was mentally disturbed and left the home a couple of days.

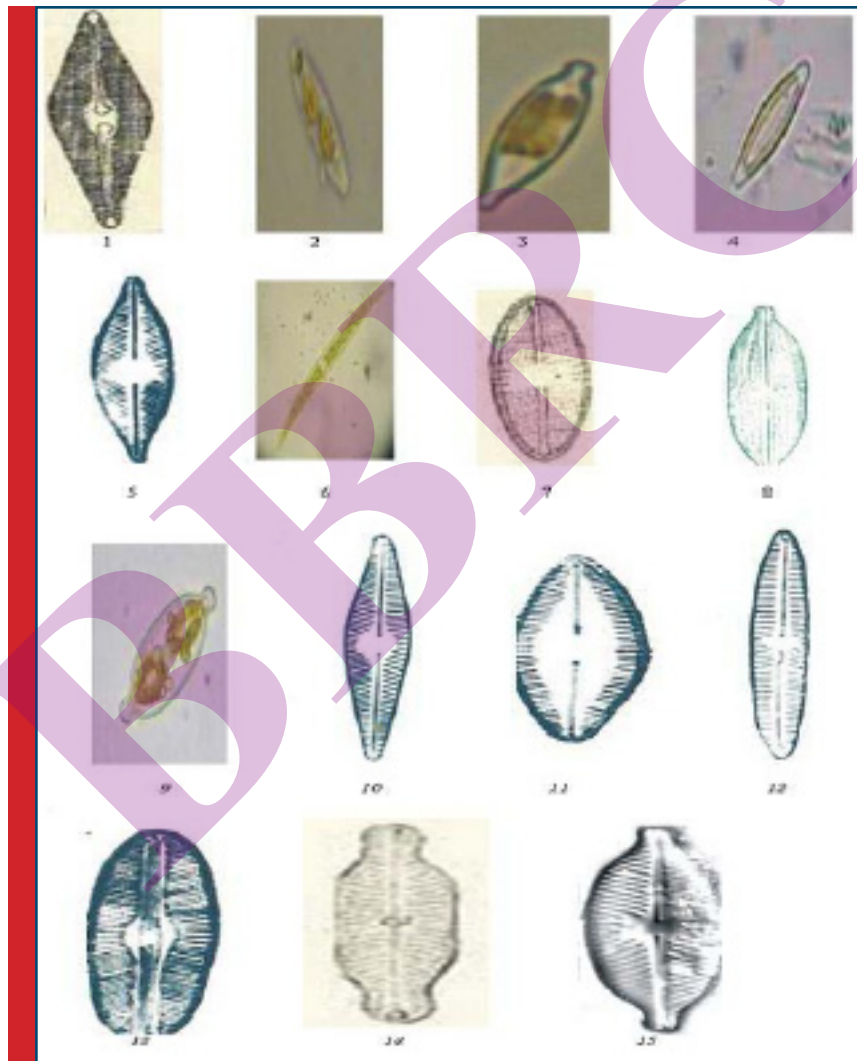
CASE 11

A highly putrefied body of 25 year old male was recovered from a canal. No information about causes of death was obtained at autopsy. Studies from extracts of nitric acid of sternum, clavicle and femur bones proved the presence of *Aulacoseria cocconies*. Water samples from

multiple sites were sent to the laboratory to trace the original site of drowning. Same diatom species was found in the water sample from a site distant from the site from where the body was recovered. The cause of death was drowning which was also proved by further police investigation.

Case No	Age	Caste	Police Station	Water Sample	Bone Sample	Diatoms in Bone sample	Diatoms in Water Sample	Result
01	19	Hindu	Gandhi Nagar Jammu	Water	Sternum	Navicula lanceolata, Navicula oblonga and Gomphonema gracile	Navicula lanceolata, Navicula oblonga and Gomphonema gracile	+ve
02	21	Muslim	Baghat	Water	Sternum	Absent	Not Required	-ve
03	18	Muslim	Humhama	Water	Sternum	Absent	Not Required	-ve
04	25	Hindu	Sambha	Water	Femur	Absent	Not Required	-ve
05	20	Sikh	Budgam	Water	Sternum	Absent	Not Required	-ve
06	26	Muslim	Nowhatta	Water	Sternum	Absent	Not Required	-ve
07	23	Hindu	Kachi Chawni	Water	Sternum	Nitzschia gracilis, Cymbella and Navicula radiosa	Nitzschia gracilis, Cymbella and Navicula radiosa	+ve
08	22	Hindu	Poonch	Water	Sternum	Absent	Not Required	-ve
09	21	Hindu	Narwal	Water	Sternum	Absent	Not Required	-ve
10	48	Hindu	Vidata Nagar	Water	Sternum	Cymbella cymbiformis, Gomphonema spheroporum and Nitzschia frustulum	Cymbella cymbiformis, Gomphonema spheroporum and Nitzschia frustulum	+ve
Case No	Age	Jammu	Police Station	Water Sample	Bone Sample	Diatom in Bone sample	Diatom in Water Sample	Exam Result
11	50	Caste	Police Station	Water	Sternum	Absent	Not Required	-ve
12	42	Hindu	Narwal	Water	Sternum	Absent	Not Required	-ve
13	35	Muslim	Rajouri	Water	Sternum	Absent	Not Required	-ve
14	25	Sikh	Channi	Water	Sternum	Absent	Not Required	-ve
15	29	Hindu	Bantalab	Water	Sternum Femur	Cymbella ventricosa and Cocconeis placentula	Cymbella ventricosa and Cocconeis placentula	+ve
16	31	Hindu	Bathandi	Water	Sternum	Absent	Not Required	-ve
17	29	Muslim	Saddar	Water	Sternum	Absent	Not Required	-ve
18	39	Muslim	Shergarhi	Water	Sternum	Absent	Not Required	-ve
19	41	Hindu	Kothi Bagh	Water	Sternum	Absent	Not Required	-ve
20	28	Christian	Sonwar	Water	Sternum	Amphora; Apibleura and Aulacoseria	Amphora; Apibleura and Aulacoseria	+ve
21	22	Hindu	Channi	Water	Femur	Absent	Not Required	-ve
Case No	Age	Hindu	Bhagwati Nagar	Water Sample	Bone Sample	Diatom in Bone sample	Diatom in Water Sample	Exam Result
22	25	Caste	Police Station	Water	Sternum	Absent	Not Required	-ve
23	26	Hindu	Kistwar	Water	Sternum	Absent	Not Required	-ve

24	16	Hindu	Channi	Water	Sternm	melosira and Hantzschna	melosira and Hantzschna	+ve
25	25	Muslim	Gojwara	Water	Sternm	Absent	Not Required	-ve
26	28	Muslim	Hawal	Water	Sternm	Absent	Not Required	-ve
27	34	Hindu	Gujar Nagar	Water	Sternm	Absent	Not Required	-ve
28	35	Hindu	Gandhi Nagar	Water	Sternm	Eunotia and Epithemia	Eunotia and Epithemia	+ve
29	45	Hindu	Channi	Water	Sternm	Anphora	Anphora	+ve
30	25	Hindu	Rangreth	Water	Sternm	Aulacoseria cocconies	Aulacoseria cocconies	+ve
31	28	Muslim	Kupwara	Water	Sternm	Absent	Not Required	-ve



1. *Navicula cuspidata*, 2. *Navicula platystoma*, 3. *Navicula radiosa*, 4. *Navicula cryptocephala*, 5. *Navicula Salinarum*, 6. *Navicula virudula*, 7. *Naviacula mutica*, 8. *Navicula protract*, 9. *Navicula gastrum*, 10. *Navicula rhyncocephala*, 11. *Navicula confevacae*, 12. *Navicula gracilis*, 13. *Navicula dicephala*, 14. *Navicula bacillum* & 15. *Navicula exiqua*.

Role of diatoms has always remained significant in solving the drowning cases. In cases, where the cause of death cannot be ascertained by conventional post-mortem examination in those cases presence of diatoms in sternum and other body tissues plays an important role in determining whether the death is due to drowning or not. Diatoms are unicellular plankton having a cell wall made of silicon dioxide. The glass frustule is composed of two valves, which fit together with the help of a cingulum, or set of girdle bands. There are about 10,000 species and 174 genera of diatoms reported which are having different shapes and sizes varying from 1 to 500µm (Rohn and Frade, 2006).

Diatoms are traditionally divided into two orders: centric diatoms (Centrales), which are radially symmetric, and pennate diatoms, which are bilaterally symmetric (Pennales) but Pollanen *et al.* (1997), classified diatoms into three classes: centric diatoms (Coscinodiscophyceae), pennate diatoms without a raphe (Fragilariophyceae), and pennate diatoms with a raphe (Bacillariophyceae). Most diatoms exist singly, although some join to form colonies. They are usually yellowish or brownish, and are found in fresh and salt water, in moist soil, and also on the moist surface of plants.

Analysis of diatoms present in the body tissues like lungs, liver, spleen, blood and bone marrow has been undertaken as supportive evidence in drowning cases. The theory behind the 'diatom test' is that when any person drowns, the diatoms present in that water will reach to the lungs and some of them because of their size penetrate into the alveoli. If the heart is still beating, the diatoms that have entered into the blood stream travel around the body and may lodge in distant organs such as the kidneys, brain and bone marrow before death (Auer, 1991; Pollanen, 1997).

The presence of diatoms in the internal organs most likely confirms the ante-mortem drowning. If there is any doubt about the drowning site, then water sample from the putative site of drowning can be collected and analysed to determine the similarity of different species of diatoms in the water and the body.

For last 100 years, many scientists have employed various extraction methods individually and in combinations in order to isolate diatoms from water and tissues samples successfully. Among these approaches some of them were found to be superior to others. Nitric acid digestion is a worldwide known method for the extraction of diatoms. However, it is important to remember that the absence of diatoms does not immediately rule out drowning; the test does not prove the negative, and a thorough investigation is always required. Again, if specific types of diatoms recovered from the marrow can be matched with those found at the suspected drowning site, the results might implicate a particular locale

of submersion and help identify the death scene, which in turn could lead to additional forensic evidence. The presence of diatoms can also corroborate investigative evidence in making accident determinations, (Pollanen, 1997; Rohn and Frade 2006).

CONCLUSION

During the present study it is concluded that among the examined cases, 31 human cases were suspected for drowning, 09 cases were positive (death due to drowning) while 22 cases were negative. The reason for the positive results was the presence of diatoms in their sternum which was detected by nitric acid method.

REFERENCES

- Auer A (1991) Qualitative diatom analysis as a tool to diagnose drowning. *Am J Forensic Med Pathol* 12: 213-218.
- Bhaskar GR (1965). Diatoms in Cases of Drowning. *JIA FS* 4: 3-5.
- Foged N (1983) Diatoms and drowning--once more. *Forensic Sci Int* 21:153.
- Peabody AJ (1978) Diatoms in forensic science. *J Forensic Sci Soc* 17: 81-87.
- Peabody AJ (1978) Diatoms in forensic science. *J Forensic Sci Soc* 17: 81-87.
- Pollanen MS, Cheung L, Chaisson DA. The diagnostic value of the diatom tests for drowning. I. Utility: a retrospective analysis of 771 cases of drowning in Ontario, Canada, *J Forensic Sci* 1997; 42:281-5.
- Pollanen MS (1997) The diagnostic value of the diatom test for drowning, II.
- Pollanen MS (1997) The diagnostic value of the diatom test for drowning, II. Validity: analysis of diatoms in bone marrow and drowning medium. *J Forensic Sci* 42:286-290.
- Rohn EJ and Frade PD (2006) The Role of Diatoms in Medico legal Investigations: Drowning, The Forensic Examiner Fall.
- Schellmann B, Sperl W (1979) [Detection of diatoms in bone marrow (femur) of no41. Foged N (1983) Diatoms and drowning--once more. *Forensic Sci Int* 21:153.
- Schellmann B, Sperl W (1979) [Detection of diatoms in bone marrow (femur) of no41.
- Hürlimann J, Feer P, Elber F, Niederberger K, Dirnhofer R, (2000) Diatom detection in the diagnosis of death by drowning. *Int J Legal Med* 114: 6-14. ndrowned [author's transl]. *Z Rechtsmed* 83: 319-324. 31.
- Schneider V. Detection of diatoms in the bone marrow of non-drowning victims. *Z Rechst* 1980; 85:315-7.
- The History, Contemporary Science, and Application of the Diatom Test for Validity: analysis of diatoms in bone marrow and drowning medium. *J Forensic Sci* 42:286-290.
- Timperman J (1969). Medico-legal problems in death by drowning: Its diagnosis by the diatom method, *J. Forensic Med.*, 16(2):45-75.
- Verma K (2013) Role of Diatoms in the World of Forensic Science. *J Forensic Res* 4: 181. doi:10.4172/2157-7145.1000181.