

## The oral and maxillofacial manifestation and surgical consideration in Maroteaux Lamy syndrome (mucopolysaccharidosis VI): A case report

Farnoosh Mohammadi, DDS, OMFS<sup>1</sup> and Iman Tavakoli DDS<sup>2\*</sup>

<sup>1</sup>Assistant Professor, Department of Oral and Maxillofacial Surgery of Tehran University of Medical Sciences, Tehran, Iran

<sup>2</sup>Resident of Oral & Maxillofacial Surgery, Department of Oral and Maxillofacial Surgery, Craniomaxillofacial Research Center, Tehran University of Medical Sciences, Tehran, Iran

### ABSTRACT

The role of the genetic disorders in maxillofacial manifestations is well documented. Maroteaux Lamy syndrome (mucopolysaccharidosis VI) is a metabolic and chromosomal abnormality which involving disturbances in mucopolysaccharide metabolism and storage of acid mucopolysaccharide in various tissues. The main factor for Maroteaux Lamy syndrome is deficiency of arylsulfatase B. Deposition of mucopolysaccharides leads to a progressive disorder which has several oral and dental manifestations including condylar hypoplasia, long-coarse face, anterior open bite, cranial deformity, macroglossia, malposition teeth, gingival fibromatosis and under-developed maxillary sinus. Also, a large head, short neck and corneal opacity are the main characteristic features. In this study a case of 4 years old girl with Maroteaux-Lamy syndrome with emphasis on oral and maxillofacial manifestations and practical surgical hints for correction of maxillofacial deformity introduced.

**KEY WORDS:** MAXILLOFACIAL MANIFESTATION, SURGICAL CONSIDERATION, MAROTEAUX LAMY SYNDROME

### INTRODUCTION

MaroteauxLamy syndrome or mucopolysaccharidosis (MPS) type VI is a rare genetic disorder with autosomal recessive transmission was first described in 1963 (Maroteaux et al. 1963). This syndrome characteristic by

deficiency of arylsulfatase B (N-acetylgalactosamine-4-sulfatase), which results in the accumulation of dermatan sulfate and chondroitin 4-sulfate within lysosomes of the connective tissues occurs (Azevedo et al. 2004; Valayannopoulos et al. 2010). The somatic features of in the Maroteaux-Lamy syndrome patients is similar to

#### ARTICLE INFORMATION:

\*Corresponding Author: [iman1122@gmail.com](mailto:iman1122@gmail.com)

Received 1<sup>st</sup> Feb, 2017

Accepted after revision 14<sup>th</sup> June, 2017

BBRC Print ISSN: 0974-6455

Online ISSN: 2321-4007 CODEN: USA BBRCBA



Thomson Reuters ISI ESC and Crossref Indexed Journal

NAAS Journal Score 2017: 4.31 Cosmos IF : 4.006

© A Society of Science and Nature Publication, 2017. All rights reserved.

Online Contents Available at: <http://www.bbrc.in/>

the other mucopolysaccharidosis (Roberts et al. 1984) however it is distinguished by the existence of normal intelligence, prominent metachromatic inclusions in leukocytes as well as lack of arylsulfatase B (Alpoz et al. 2006). Arylsulfatase B plays critical role in degradation of glycosaminoglycans (GAG) such as dermatan sulfate and chondroitine sulfate (Neufeld et al. 1995; Valayanopoulos et al. 2010). The etiology of MPS type VI is mutation in arylsulfatase B gene which is located on the chromosome 5q13-5q14 (Litjens et al. 1989). The anatomic feature of the disease is characteristic with growth retardation, hernias, typical facies, a large deformed head with short neck and spinal abnormalities (Valayanopoulos et al. 2010, Fonseca et al. 2014).

In the sever condition, death can happen in result of cardiac disease or respiratory tract infection (Wiedemann et al. 1992). In this study a case of 4 years old girl with Maroteaux-Lamy syndrome with emphasis on oral and maxillofacial manifestations and practical surgical hints for correction of maxillofacial deformity introduced.

## CASE REPORT

### BASIC INFORMATION

A 4 year and 6 months-old girl with Maroteaux-Lamy syndrome was admitted to the Children's Medical Center of Tehran University of Medical Science, Tehran, Iran. She was the only child of a young couple with no consanguinity. They were aware of traits of syndrome since 3 years ago. Small size, disability in extension of upper and lower limb and abnormal facial appearance were the initial symptoms mentioned by the parents. Investigations revealed no cardiac, ophthalmic, mental or hearing disorder. She was not able to walk because of short stature, generalized dysostosis and joint deformity. She had no mental deficit but she was not able to speak. Huge gin-

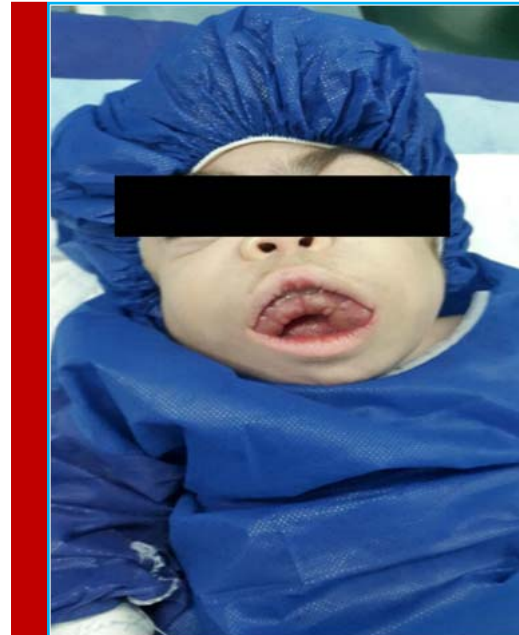

FIGURE 1. Severe gingival overgrowth is obvious in clinical examination.

gival overgrowth, macroglossia and abnormal anatomy were contributed to her speechless. Oral and maxillofacial manifestations include large head, long coarse face, hypertelorism, bushy eyebrows, deep nasojugal fold, marked open bite and open mouth breathing, infra-erupted teeth and gross gingival fibromatosis (Figure 1). The weight of the patient before the surgery was 7.8kg. The lysosomal enzyme analysis showed decreased activity of arylsulfatase B in blood sample was determine using arylsulfatase B enzyme assay (normal 300-900 nmol/h/mg) (Baum et al. 1959). The blood arylsulfatase B was 0.14 - 0.70 nmol/21h. The 3D computed tomography (CT) scan showed displaced position of teeth, hypoplastic condyle and dysmorphic cranio-maxillofacial skeleton (Figure 2, 3). An

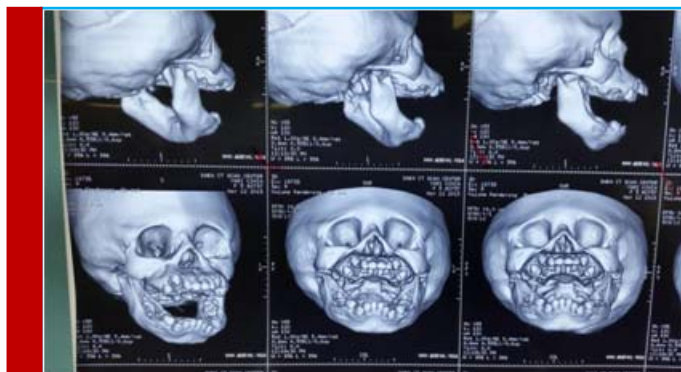


FIGURE 2. 3D CT scan of the patient in frontal and sagittal view, malposition teeth and skeletal open-bite are considerable.

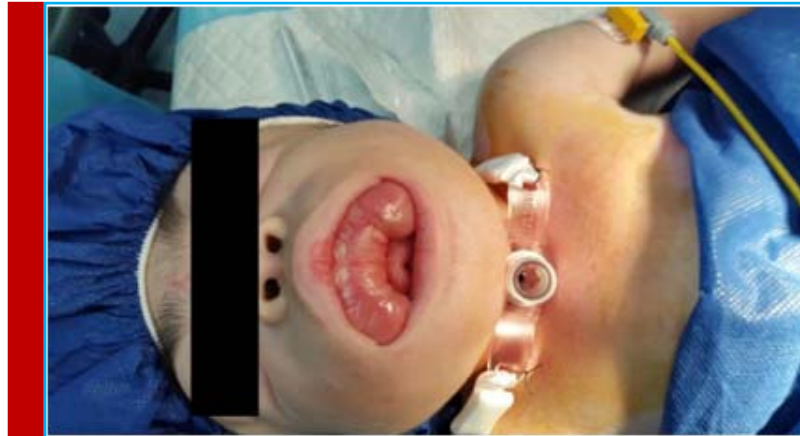

FIGURE 3. Tracheostomy was carried out to provide a secured air way.

elective tracheostomy was performed was done under general anesthesia (Figure 4). Skin stiffness, rigidity of trachea and narrowing of air passage during procedure were considerable. Short neck and small stature made the procedure more difficult. Gingivectomy was done in a large scale for each quadrant (Figure 5, 6).

### SURGERY PROCEDURE

The blade no.15 followed by the blade no.10 was applied for the last three quadrants due to thickness and inelasticity of gingival tissue. Most of the incisor teeth were infra-erupted because of gingival overgrowth and the other teeth were impacted. Some teeth contained large and thick follicle like a dentigerous cyst. Malpositioning of impacted teeth, underdeveloped maxillary sinus, taurodontism and thin cortical bone in buccal area of mandibular molar were revealed during surgical exploration. After gingivectomy, all the teeth were extracted and the bone was shaved and reshaped. After opera-

tion, the patient was admitted to the intensive care unit (ICU) and intubated. 3 weeks after surgery when she was ready to wean from mechanical ventilation, extubation was carried out but a few minutes after extubation, oxygen saturation decreased, she became cyanotic and the ICU staffs were not able to re-intubate her because of bronchospasm.

### DISCUSSION

The MPS type VI is an inborn metabolic and autosomal recessive disease caused by mutations in the arylsulfatase B gene (Alpoz et al. 2006). A mutation in chromosome 5 is responsible to this syndrome (Baehner et al. 2005). This enzyme is called N-acetyl galactosamine 4-sulfatase which plays an important role in metabolism of GAG (Malm et al. 2007). This gene is required for the degradation of dermatan sulfate and deficiency leads to cumulation of undegraded or partially degraded

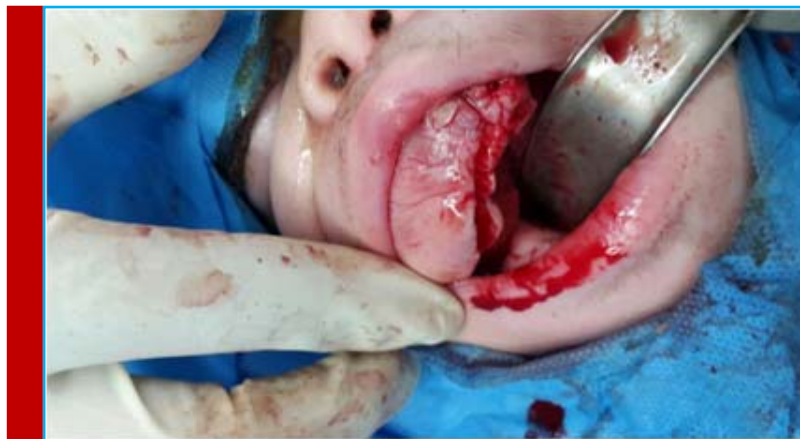

FIGURE 4. Soft tissue removal for 1 quadrant of upper jaw.

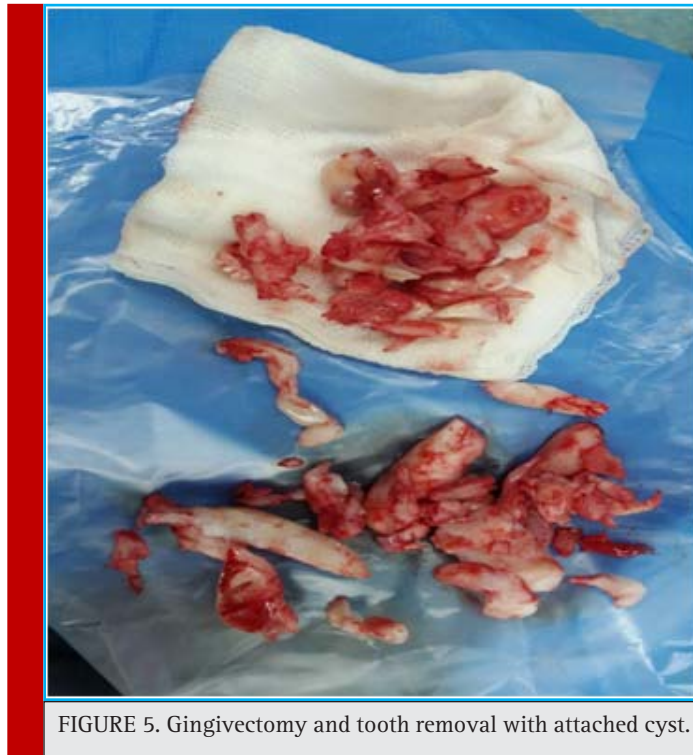

FIGURE 5. Gingivectomy and tooth removal with attached cyst.

mucopolysaccharides which results in large lips and thick gingival tissue and corneal opacities (Alpoz et al. 2006). It is reported the frequency of the MPS type VI ranges from 1:100 000 births to 1:1300 000 in various populations (Meikle et al. 1999).

Diagnosis of the MPS type VI is based on clinical manifestation and paraclinical evaluation. The cardiac disease is common phenomenon in these patients. Based on the previous reports in a population of 28 patients with MPS type VI mitral valve stenosis was the most common cardiac problem, however, patient showed a normal cardiac function (Azevedo et al. 2004). Pulmonary diseases are other important problems in this syndrome. Nasopharyngeal space is decreased due to vertical facial skeleton overgrowth and deposition of GAG which may lead to respiratory difficulty (Fonseca et al. 2014). Special consideration should be taken on airway management in these patients during general anesthesia because of difficult intubation. Tracheostomy is recommended in severe cases. Short and inflexible neck, narrow trachea and tracheomalacia can make this procedure more difficult. Special note should be focused on extubation in these cases. Although ophthalmological and hearing problems are frequently seen in these patients, in the current study, our patient had none of these problems. Severe skeletal problems and growth retardation were observed in this case. She had bilateral fixed flexed hips and also was not able to extend the neck or the

arms. Very small stature and low weight (7.8 kg) with age of 4 years and 6 months were remarkable.

Craniofacial dysmorphism are characteristic in Maroteaux-Lamy syndrome. Large head, coarse facial appearance, bushy eyebrow, deep nasojugal groove and hypertelorism are the main of these features. Dolichocephalic growth pattern causes to decrease nasopharyngeal space and leads to dyspnea (Fonseca et al. 2014). Also, underdeveloped condyle, macroglossia and huge gingival fibromatosis were contributed to open bite. Magnetic resonance imaging revealed cartilage proliferation in the retrodiscal tissue and anterior disk displacement (Cavaleiro et al. 2013). Several dental problems such as impacted teeth, buccally inclined teeth, cyst-like follicle, malposition teeth and taurodontism are reported (Alpoz et al. 2006). In this case, extraction of most of the teeth was inevitable. Huge gingival fibromatosis and follicular formation around the crown of the teeth had made the eruption of the teeth impossible. It is reported early enzyme replacement therapy in siblings have beneficial effects on facial morphology, joint mobility and cardiac valve pathology (McGill et al. 2010).

In conclusion, despite Maroteaux-Lamy syndrome is not encountered routinely in dental practice, such cases, if properly managed, will maintain their oral and general health for the remainder of their lives. So, this studied revealed the importance of screening in newborns but surgical treatment in many cases is required.



## REFERENCES

- Alpoz A, Coker M, Celen E, Ersin NK, Gokcen D, Diggelenc OP, Jan G, Huijmansc M (2006). The oral manifestations of Maroteaux-Lamy syndrome (mucopolysaccharidosis VI): A case report. *Oral Surg Oral Med Oral Pathol Oral Radiol Endod.* 101:632-7.
- Azevedo AC, Schwartz L IV, Kalakun L, Brustolin S, Burin MG, Beheregaray AP, Leistner S, Giugliani C, Rosa M, Barrios P, Marinho D, Esteves P, Valadares E, Boy R, Horovitz D, Mabe P, da Silva LC, de Souza IC, Ribeiro M, Martins AM, Palhares D, Kim CA, Giugliani R (2004). Clinical and biochemical study of 28 patients with mucopolysaccharidosis type VI. *Clin Genet.* 66:208-13.
- Baehner F, Schmiedeskamp C, Krummenauer F, Miebach E, Bajbouj M, Whybra C, Kohlschütter A, Kampmann C, Beck M (2005). Cumulative incidence rates of the mucopolysaccharidoses in Germany. *J Inherit Metab Dis.* 28:1011-17.
- Baum H, Dodgson KS, Spencer B (1959). The assay of arylsulphatase A and B in human urine. *Clin Chim Acta*;4:453-5.
- Cavaleiro RM, Pinheiro Md, Pinheiro LR, Tuji FM, Feio Pdo S, de Souza IC, Feio RH, de Almeida SC, Schwartz IV, Giugliani R, Pinheiro JJ, Santana-da-Silva LC (2013). Dentomaxillofacial manifestations of mucopolysaccharidosis VI: clinical and imaging findings from two cases, with an emphasis on the temporomandibular joint. *116:* 141-8.
- Fonseca FR, de Santana Sarmiento DJ, Vasconcelos Medeiros PF, Diniz DN, dos Santos MT (2014). Patients with mucopolysaccharidosis have tendencies towards vertical facial growth. *J Oral Maxillofac Surg.* 72: 2539-46.
- Litjens T, Baker EG, Beckmann KR, Morris CP, Hopwood JJ, Callen DF (1989). Chromosomal localization of ARSB, the gene for human N-acetylgalactosamine-4-sulphatase. *Hum Genet.* 82:67-8.
- Malm G, Lund AM, Mansson JE, Heiberg A (2008). Mucopolysaccharidoses in the Scandinavian countries: incidence and prevalence. *Acta Paediatr.* 97:1577-81.
- Maroteaux P, Leveque B, Marie J, Lamy M (1963). A new dysostosis with urinary elimination of chondroitin sulfate B. *Presse Med.* 71:1849-52.
- McGill JJ, Inwood AC, Coman DJ, Lipke ML, de Lore D, Swiedler SJ, Hopwood JJ (2010). Enzyme replacement therapy for mucopolysaccharidosis VI from 8 weeks of age--a sibling control study. *Clin Genet.* 77:492-8.
- Meikle PJ, Hopwood JJ, Clague AE, Carey WF (1999). Prevalence of lysosomal storage disorders. *JAMA.* 281:249-54.
- Neufeld EF, Muenzer J (1995). The mucopolysaccharidoses. The metabolic and molecular bases of inherited disease. New York: McGraw-Hill. 2465-94.
- Roberts MW, Barton NW, Constantopoulos G, Butler DP, Donahue AH (1984). Occurrence of multiple dentigerous cysts in a patient with the Maroteaux-Lamy syndrome (mucopolysaccharidosis, type VI). *Oral Surg Oral Med Oral Pathol Oral Radiol Endod.* 58:169-75.
- Valayannopoulos V, Nicely H, Harmatz P, Turbeville S (2010). Mucopolysaccharidosis VI, Orphanet. *J Rare Dis.* 5:5-20.
- Wiedemann HR, Kunze J, Grosse FR, Dibbern H (1992). An atlas of clinical syndromes (a visual aid to diagnosis). Aylesbury: Wolfe Publishing Co. p. 58.